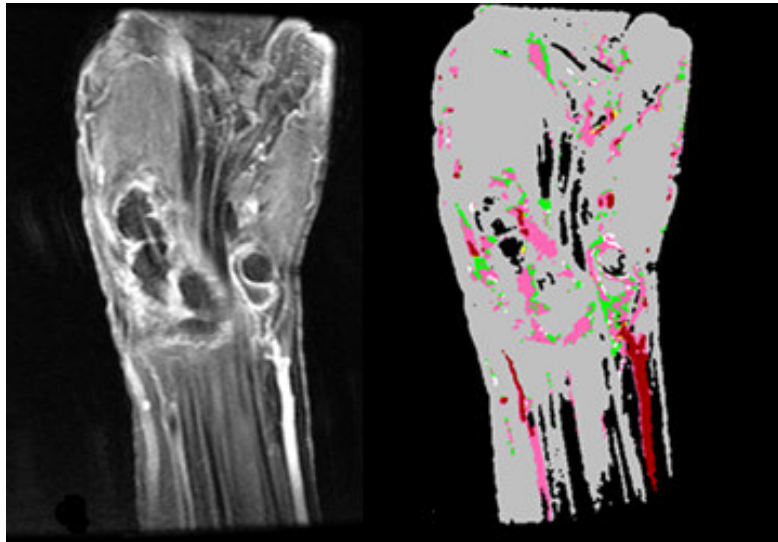


QUANTIFICATION OF SYNOVITIS IN HAND USING DYNAMIC CONTRAST ENHANCED MRI


Dynamic contrast enhanced MRI has a potential to quantify synovitis in patients with rheumatoid arthritis.

We challenge to visualize and quantify synovitis accurately and to reduce acquisition time via sophisticated way of analysis.



MR image

Quantification map
(■: synovitis)



Yuto KOBAYASHI