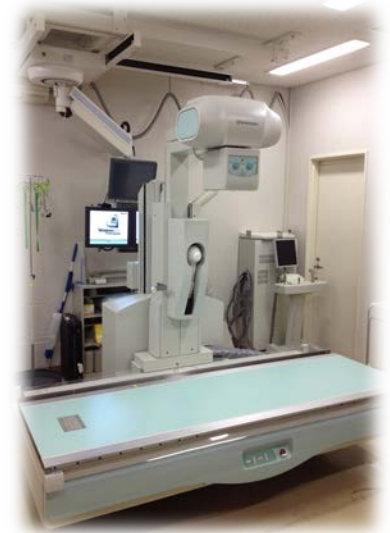


# RHEUMATOID ARTHRITIS IMAGING USING DIGITAL TOMOSYNTHESIS – A PHANTOM STUDY

Digital tomosynthesis can acquire tomograms of the selected region of the body with a single X-ray exposure.

It is expected that digital tomosynthesis depicts more lesions of early rheumatoid arthritis than radiograph.

Comparison study with radiograph and computed tomography revealed that digital tomosynthesis may be a useful modality with satisfactory lesion detection ability and reduced X-ray exposure.



Youhei ONO